Neurology

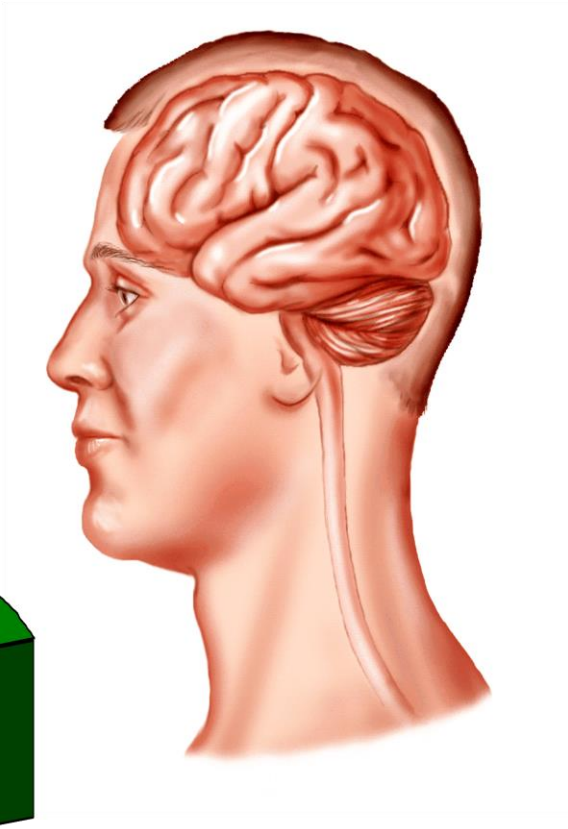

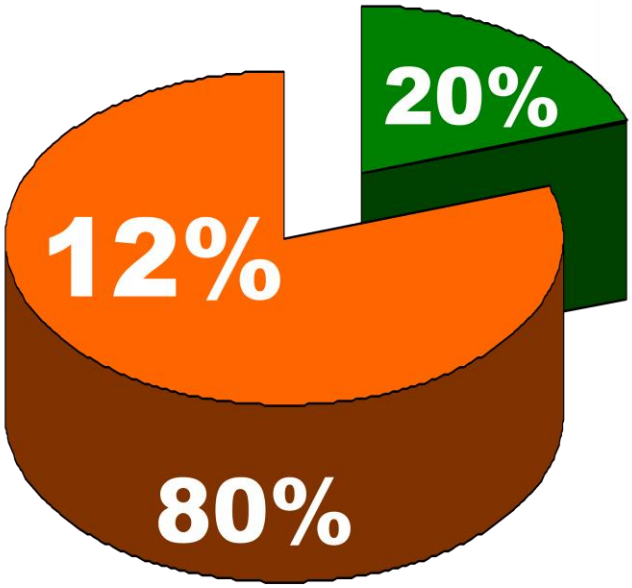

Neurology

Acknowledgement to:
Joseph Haymore, RN, MS, CNRN, CCRN, ACNP, CRNP

I. Introduction

- AACN – CCRN/CCRN-E Blueprint – 12%
  - Aneurysm
  - Brain Death (irreversible cessation of whole brain function)
  - Congenital Neurological Abnormalities (e.g. AV malformations)
  - Encephalopathy (e.g. anoxic, hypoxic-ischemic, metabolic, infectious)
  - Head Trauma (e.g. blunt penetrating, skull fractures)
  - Intracranial Hemorrhage/Intraventricular Hemorrhage (e.g. subarachnoid, epidural, subdural
  - Neurologic Infectious Disease (e.g. viral, bacterial)
  - Neuromuscular disorders (e.g. muscular dystrophy, Guillian-Barre, Myasthenia Gravis)
  - Neurosurgery
  - Seizure Disorders
  - Space-Occupying Lesions (e.g. brain tumors)
  - Stroke (e.g. ischemic, hemorrhagic)

II. Anatomy & Physiology

- Skull
- Brain
- Meninges: Dur Mater, Arachnoid, Pia Mater
- Cerebrum
- Brain Stem
- Cerebellum
- Cranial Nerves
- Blood Vessels
- Cerebral Spinal Fluid
- Spinal Cord
- Peripheral Nerves

III. Neuro Assessment (Included for Review)

A. Level of Consciousness

B. GCS 3-15

- Eye Opening - 1-4 Points
- Best Verbal Response – 1-5 Points
- Best Motor Response – 1-6 Points

C. Pupils

- Size: Sympathetic & Parasympathetic, CN II & III
- Shape
- Symmetry
- Reaction to Light
- Extra Ocular Movement: CN III, IV
- Abnormal Pupillary Findings
  - Nonreactive, Midposition: Midbrain Damage
  - Nonreactive Pinpoint: Pons Damage
  - Reactive, Small & Equal: Damage Affecting Sympathetic Innervation
  - One Fixed & Dilated Pupil: Same Side CN III Compression or Injury
  - Bilateral Fixed & Dilated Pupils: Severe Brain Compression, Ischemia and/or Anoxia
  - Oculocephalic Reflex (doll's eyes): Absent reflex or neg doll's eyes = brainstem injury
    - Turn the Head of an Unconscious Patient with Eyes Open
    - + Doll's Eyes (which is good): Eyes Continue to Look Straight Ahead (don't turn with the head). Patient has a positive oculocephalic reflex
    - - Doll's Eyes (which is bad): Eyes turn with the head (as though they were painted on the face of the doll and unable to move). Patient had a negative oculocephalic reflex

D. General Observation

- Behavior
- Mood/Affect
- Appearance
- Communication Pattern and Style
- Organized Flow of Thoughts

E. Motor & Sensory

F. Cognitive Function

- Orientation
- Memory & Retention
- Attention
- Abstract Reasoning
- Judgment

G. Language & Communication

- Aphasias
  - Expressive Aphasia (Brocca's) – Dominant Frontal Lobe
  - Receptive Aphasia (Wernicke's) – Dominant Temporal Lobe

H. Respiratory Patterns

- Cheyne-Strokes Breathing: Problem in Cerebral Hemispheres, Diencephelon or Basal Ganglia
- Neurogenic Hyperventilation: Midbrain or Upper Pons Problems
- Apneustic Breathing: Pons Lesion (prolonged inspiration with pauses)

I. Posturing

1. Decerebrate
2. Decorticate

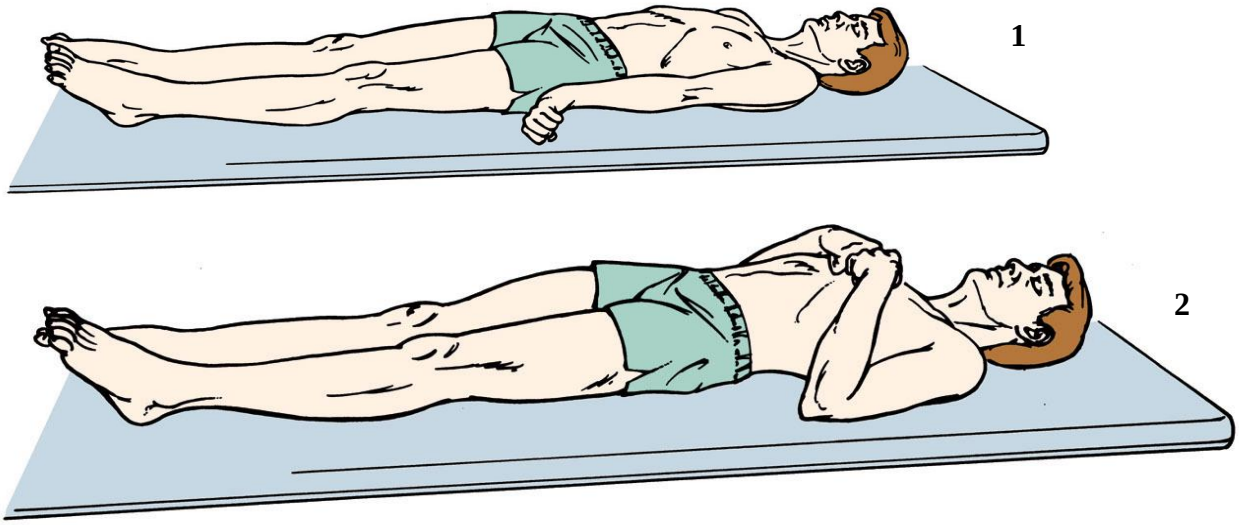

J. Cranial Nerves

#	CRANIAL NERVE	FUNCTION	ASSESSMENT
I	Olfactory	Smell	Evaluate Ability to Identify Odors
II	Optic	Vision	Evaluate Sight
III	Occulomotor	Eye Movement Pupil Constriction Elevation of Eye Lid	Evaluate Eye Movement Towards Nose Up and In, Down and In
IV	Trochear	Eye Movement	Evaluate Eye Movement Downward and Inward
V	Trigeminal	Sensation to Face Muscles of Matriculation Corneal Reflex	Tighten Jaw (Clench Teeth)
VI	Abducens	Eye Movement	Evaluate Eye Movement Laterally Outward
VII	Facial	Muscles of Face Taste Anterior Tongue	Demonstrate Facial Expressions Show Teeth
VIII	Acoustic	Vestibular – Balance Cochlear – Hearing	Evaluate Hearing
IX	Glossopharyngeal	Pharyngeal Reflex (gag) Taste Posterior Tongue Swallowing	Swallow Evaluate Gag
X	Vagus	Parasympathetic Innervation Swallowing	Assessed with Glossopharyngeal
XI	Spinal Accessory	Sternocleidomastoid & Trapezius Muscle Movement	Shrug Shoulders Rotate Head
XII	Hypoglossal	Movement of Tongue	Check Speech

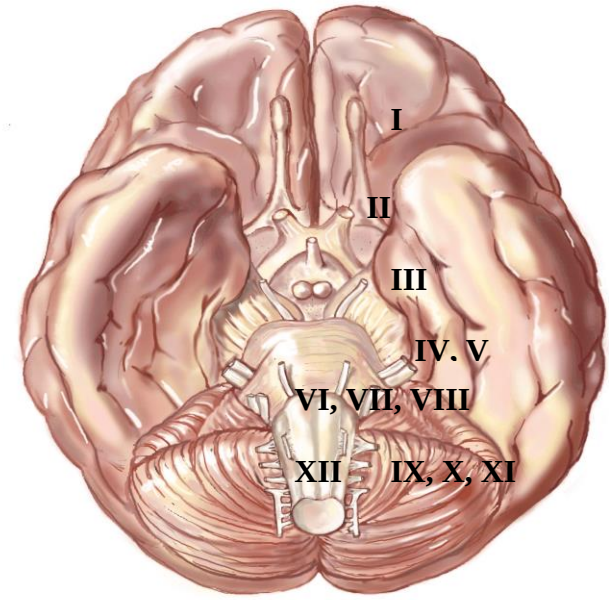

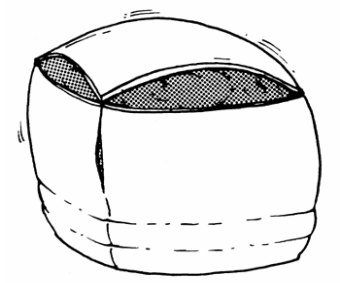

IV. ICP Monitoring

A. Monroe Kellie Hypothesis

Skull is a Rigid Box

- Brain 80%
- Blood 10%
- CSF 10%
- Pressure is Dynamic
- Increase in any Component will Result in Increase in Pressure

Acidosis pH = Cerebral Vasodilation
Alkalosis pH = Cerebral Vasoconstriction

B. Normal ICP is 0-15mmHg

C. Herniation Syndromes

- Cingulated: Cingulate Gyrus Under the Falx Cerebri Under the Flax Cerebri
- Transtentorial (Uncal): Uncus of Temporal Lobe into Tentorial Notch (Downward). Pupils dilate on same side (first sign)
- Central: Downward Displacement of Brainstem. Change in LOC first then pupils dilate

D. Clinical Signs of Increased ICP

- Early Changes
  - Altered LOC
  - Headache
  - Nausea & Projectile Vomiting

- Late Changes
  - Focal Changes
    - Language Difficulties
    - "Drift"
    - Motor Weakness
    - Facial Weakness
    - Visual Changes

  - Pupillary Changes
    - Dilated Pupil on Side of Lesion
    - Small Pupils (pontine problem)

- Eye Movements
    - Forced Gaze Toward Lesion

- Vital Sign Changes (Cushing's Triad)
    - Widening Pulse Pressure
    - Bradycardia
    - Irregular Respirations

- Posturing
    - Flexor or Decorticate (lesion in mesencephalic region - midbrain)
    - Extensor or Decerebrate (lesion or compression to brainstem)

E. Cerebral Perfusion Pressure (CPP)

- CPP = MAP – ICP
- Goal CPP > 60-70mmHg, ICP < 20mmHg

F. ICP Monitoring

- Detect Changes in ICP Before Clinical Changes Occur
- Drainage of Fluid
- Guidance & Evaluation of Interventions & Management
- Types
    - Epidural
    - Subdural
    - Subarachnoid
    - Intraparenchymal
    - Intraventricular (ventriculostomy – gold standard)
- Nursing Care for Pt with Increased ICP & Ventriculostomy
    - Promote Venous Drainage
    - Head Midline
    - Avoid Excessive Hip Flexion
    - Minimize & Cluster Nursing Activities
    - Close System when Suctioning, Changing HOB, Turning, etc.
    - Consistent Zero Point (transducer): lateral ventricle – temple in front of ear (Foramen Monroe or Interventricular Foramen)
    - STRICT Aseptic Technique

G. Management of Increased ICP

- Promote Cerebral Perfusion
  - HOB Flat
- Promote Venous Drainage
  - HOB $30^0 – 45^0$
  - Head in Neutral Alignment
- Reduce Cerebral Tissue Demands
  - Treat Pain/Agitation
  - Treat Temp > 37.5^0
  - Caution with Valsalva Maneuvers
  - Basic Hygiene
- Prevent Hypoxemia
- Avoid Hypercarbia (acidosis = vasodilation)
- Hyperventilation – Controversial
  - Normal $PaCO_2$ = 35-45
  - Decrease to 30-35 is Common
  - Do Not Use > 6 – 24 hours
- PEEP
  - Increases in PEEP also Increases ICP
  - Use Cautiously
- Maintain
  - MAP > 80 mmHg
  - CPP > 60-70 mmHg
  - ICP < 20mmHg
- Maintain Euvolemia
  - Crystalloids vs Colloids
- Arrhythmias Management
- Medications
  - Osmotic Therapy
  - Hypertension
  - Hypotension
  - Glucocorticoid Steroids - only for Tumors
  - Sedatives
  - Neuromuscular Blockade (NMB)

H. **Hydrocephalus:** Abnormal accumulation of cerebrospinal fluid within the head causing increased pressure and dilation of the ventricles. The increase in CSF is caused from <u>increased production, decreased reabsorption or obstruction to flow.</u>

Common Causes

- Congenital Anomalies
- Intracranial Infections
- Meningitis
- Traumatic Brain Injury
- Brain Tumors
- Intracranial Bleeding

Clinical Presentation

- S&S Develop Over Days→Weeks
- Increased ICP (refer to earlier content)
- Seizure
- Headache
- Edema of Optic Disc
- Strabismus (one or both crossed eyes – weak or dysfunctional eye muscle(s)
- Decline in Motor Function: Paresis → Plegia → Posturing
- Loss of Muscular Coordination

Diagnosis

- Head CT/MRI
- Angiography

Treatment

- Correct Obstruction
- Maintain ICP Below 20mmHg
- Drain CSF (ventriculostomy)
- Lumbar Drain to Remove CSF
- Ventriculoperitoneal Shunt Placement
- Prevent Complications

V. Brain Attack AKA Stroke

Time Is Brain



A. Definitions

- Stroke
  Permanently impaired central nervous system (CNS) tissue/functioning due to impaired cerebrovascular perfusion
- Transient Ischemic Attack (TIA)
  Lasts for minutes to hours
  No detectable dysfunction or tissue damage
- Penumbra:
  Viable but not functioning neuronal cells
  This area may recover and not progress to stroke

B. Risk Factors

- Age
- Hypertension
- Atrial Fibrillation
- Dyslipidemia
- Diabetes Mellitus
- Coronary Artery Disease
- Sedentary Lifestyle
- Smoking
- Obesity
- Valvular Disease

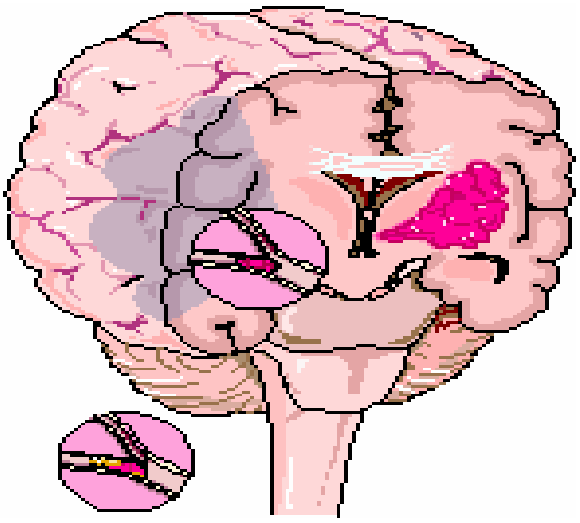

C. Causes of Ischemic Stroke

- Thrombotic
  - Atherosclerosis
  - Vasculitis
  - Arterial Dissection
  - Hematologic Disorders
- Embolic
  - Cardiogenic
  - Athero-thrombotic Arterial Source
  - Unknown Source: Hypercoagulable State

D. Initial Assessment

- Goals
  - Rapid Assessment
  - Initiate Treatment

- Assessment
  - ABC's
  - Vital Signs
  - Cardiac Monitor
  - Accurate Event History
  - Presentation (language, motor, sensory)

- Common Stroke Signs: Sudden
  - Rarely Loss Consciousness
  - Asymmetrical Facial Expression
  - Weakness on One Side of the Body
  - Numbness on One Side of the Body
  - Difficulty Speaking or Understanding
  - Difficulty Walking
  - Visual Difficulty: Homonymous Hemianopia, visual field cut same side as stroke
  - Severe, Unexplained Headache

- Tests
  - CT Scan (no contrast)
  - MRI
  - Transcranial Doppler
  - Blood Work

E. Ischemic Stroke Care

- Hypertension
  - Normal Response to Stroke
  - Usually Resolves in 3-4 days
  - Some HTN is Good
  - Only tx if SBP >220, DBP > 140 or MAP >130
  - Unless t-PA: SBP > 185, DBP > 110
- Do Not Lower Blood Pressure > 10 % per hour
- Activase (alteplase or rt-PA)
  - Only FDA Approved Therapy
  - Within 3 Hrs of Onset, up to 4.5 hr for certain pts
  - No ASA, Heparin, etc x 24 Hours
- Interventions
  - Treat Hypotension
  - Treat Hyperthermia (Keep < 37.5^0 C)

- Maintain Serum Glucose 80 - 150
- Monitor ABG's and Pulse Ox
- Protect Airway
- HOB Flat Initially Then When Stable HOB > 45^0
- NPO → Swallowing Study

F. **Hemorrhagic Stroke** (Intracerebral Hemorrhage)

- Bleeding into Tissue/Parenchyma
- Commonly From Hypertension
- Signs & Symptoms
  - Severe Headache, N/V, Loss of Consciousness
  - Retinal Hemorrhage
  - Similar to Ischemic Strokes
  - Localized Blood Seen on CT
- Bleeding into the Subarachnoid Area
- Often Due to a Ruptured Aneurysm or AVM

Aneurysm

- Types
  - Fusform
  - Berry
  - Saccular
- Rupture
  - Bleeds into the Subarachnoid Space
  - Bleeding Continues Until Tamponade Occurs and Thrombus Forms

Arteriovenous Malformation (AVM)

A congenital abnormal linkage between an artery and vein. When ruptured or leaking will present the same as an intracerebral hemorrhage.

- Assessment
  - "Worst Headache of My Life"
  - N/V
  - Loss of Consciousness
  - Nucal Rigidity and Photophobia
  - Focal Deficits
  - Clinical Findings Similar to Ischemic Strokes
  - Ventricular and/or Subarachnoid Blood Seen on CT

- CSF from LP Positive for Blood
- Hydrocephalus Might Occur
- Hyponatremia Might Occur
  - SIADH
  - DI

- Medical Management
  - Diagnostic Work up
    - CT/MRI
    - Cerebral Angiogram
    - MRA
    - Transcranial Doppler
    - Lumbar Puncture
    - Laboratory Assessment
  - Strict Control of Blood Pressure
  - Pre-Repair -- MAP 80-90, BPS < 140 CPP > 60
    - Nicardipine Hydrochloride (Cardene)
    - Sodium Nitroprusside (Nipride)
    - Normodyne (Labetalol)
    - Hydralazine (Apresoline)
    - Aneurysm Precautions
    - Pain Relief
  - Post-Repair: Vasospasm – Major Concern
    - Triple H Therapy- currently lacking strong support
      Hypertensive -- MAP 120-150 and CPP > 60
      - Phenylephrine (Neosynephrine)
      - Dopamine Hydrochloride (Dopamine)
      - Norepinephrine Bitartrate (Levophed)

      Hemodilutional -- Hct of 30-33
      Hypervolemic -- CVP of 8-12
    - Calcium Channel Blockers
    - Nimodipine: 60 mg PO q 4 hours for 21 days
    - NO Heparin, Coumadin, or ASA

VI. Neurologic Infections & Neuromuscular Disorders

A. Encephalitis: Inflammation of the Brain

- Etiology (usually viral)
  - Herpes Simplex 1
  - Arbovirus (Mosquitoes)
  - West Nile, Eastern and Western Equine, St. Louis
  - Enterovirus

- Polio, Coxsackie's
- Measles, Mumps, Rabies
- Cytomegalovirus, Vericella-Zoster
- Immunocompromised

- Clinical Presentation
  - Personality Changes
  - Behavioral Changes
  - Altered LOC
  - Focal Neurologic Deficits
  - Hallucinations (olfactory and gustatory)
    - Classic Sign of Herpes Encephalitis

- Management
  - ABCs
  - Supportive Care
  - Herpes Simplex 1 Encephalitis, Acyclovir 10 mg/kg IV q 8 hours
  - Corticosteroids - only in children
  - Seizure Management
  - Fever Management
  - Pain Management

B. Meningitis: Inflammation of the Meninges

- Etiology
  - Viral
    - Spinal Tap: CSF Normal Glucose Level
  - Bacterial
    - Pneumococcal: *Staptococcus Pneumoniae*
    - Meningococcal: *Neisseria Meningitides*
    - Spinal Tap: CSF No or Low Glucose Level
  - Aseptic
  - Fungal
  - TB

- Clinical Presentation
  - Headache
  - Altered LOC
  - Kernig's Sign – Pain with Leg Lift

- Brudzinski's Sign – Hip and Knee Flexion with Neck Flexion
- Fever
- Nucal Rigidity
- N & V
- CN Palsies
- Myalgias
- Photophobia
- Meningococcal – Skin Rash

- Management
  - Isolation
    - Bacterial Until on Adequate Abx x 24 hrs
  - Antimicrobial Therapy
  - Steroids (controversial)
    - Yes for Viral and Aseptic
    - No for Bacterial
  - Pain Management
  - Fever Management
  - Seizure Control
  - Universal Precautions

C. Guillain-Barre Syndrome (GBS)

Post-Infection Inflammatory Demyelination of Peripheral Nerves

- Common Causes
  - URI
  - Gastroenteritis
  - Viral Infections
    - Cytomegalovirus (CMV)
    - Hepatitis A, B or C
    - Epstein-Barr (EBV)
    - Human Immunosupression Virus (HIV)
  - Bacterial Infections
    - *Mycoplasma Pneumonia*
    - *Campylobacter jejuni*
  - SLE
  - Immunizations
    - Rabies
    - Tetanus

        - Influenza
    - Renal Transplantation
    - Surgery
    - Hodgkin's Disease

- Presentation
    - Paresthesias Before Paresis
    - Distal to Proximal
    - Develops Over Hrs or up to 10 Days
    - When Symptoms Peak, They Usually Persist for 2 Weeks
    - No LOC or Cognitive Changes

- Testing
    - Lumber Puncture (LP): Elevation in Protein
    - Nerve Conduction Studies: Reduction in Velocity
    - CBC, ESR, LFT, HIV, Hepatitis Panel

- Treatment
    - Respiratory Support/Ventilation
    - Plasmapheresis/Plasma Exchange
    - Intravenous Immunoglobulin (IVIG)

D. **Myasthenia Gravis**: Chronic Autoimmune Disease Affecting the Neuromuscular Junction. Reduces the number of acetylcholine receptors (ACH-R). Typical onset is Women 20-30yo and Men 60-70yo.

- **Clinical Presentation**
    - Diplopia and Ptosis
    - Fatigue with Repetition
    - Paresis
    - Proximal > Distal
    - Trouble Climbing Stairs or Raising Arms Above Head
- **Diagnosis**
    - Anti-ACH-R Antibody Titers
    - Repetitive Nerve Stimulation on Conduction Studies
    - EMG
    - Tensilon Test
        - Tensilon 10 mg over 1-2 minutes
        - Improved Symptoms = positive result

- Cardiac Monitor
- **<u>Have Atropine Available</u>**

- **Treatment**
  - CHECK BEFORE GIVING ANY DRUG: there are many drug interactions
  - Plasmapheresis
  - Thymectomy
  - Pharmacology
    - Anticholinesterase: Pyridostigmine (Mestinon)
      - Abdominal Cramps
      - Epigastric Discomfort
      - Anorexia
      - N/V
      - Diarrhea
      - Miosis (small pupils)
      - Bronchospasm
      - Salivation, Tearing
      - Spasm
      - Fasciculation
      - Weakness
    - Immunosupression
    - Intravenous Immunoglobulin

E. Amyotrophic Lateral Sclerosis (ALS) (Lou Gehrig's)

Amyotrophic: Loss of Muscle Mass, Wasting
Lateral Sclerosis: Demyelination of the Corticospinal Tracts in the Lateral Spinal Cord

Leads to

- ✓ Weakness and Atrophy
- ✓ Voluntary Skeletal Muscles
- ✓ Arms
- ✓ Legs
- ✓ Trunk
- ✓ Respiration
- ✓ Throat
- ✓ Face

- Onset
  - Lower Extremity Paresis 36%

- ◆ Upper Extremity Paresis 32%
- ◆ Dysarthria & Dysphagia 25%
- ◆ Respiratory & Truncal Paresis 7%

- Nursing Concerns
  - ◆ Airway – Need for Mechanical Ventilation
  - ◆ Nutrition
  - ◆ Communications
  - ◆ Trauma
  - ◆ Stress & Coping
  - ◆ Grief
  - ◆ Family/Support Group Counseling

VII. Seizures

A. Definitions

- Seizure
  - ◆ Uncontrolled Discharge of Neurons Which Interferes With Normal Function

- Epilepsy
  - ◆ Recurrent, Spontaneous Seizures

- Status Epilepticus
  - ◆ Recurrent Seizures Before Recovery to Baseline

B. Etiologies & Predisposing Factors

- Structural Changes
  - ◆ Trauma
  - ◆ Infections
  - ◆ Intracranial Masses

- Cerebrovascular Disease
  - ◆ Hemorrhage
  - ◆ Ischemic Stroke

- Metabolic Factors
  - ◆ Fluid and Electrolyte Imbalance
  - ◆ Hypoxia

- Acidosis
- Toxic Exposure
- Drug Overdose/ Withdrawal

C. Classifications

- Partial Seizures
  - Simple Partial
    - One Hemisphere
    - No Loss of Consciousness
  - Complex Partial
    - One Hemisphere
    - Loss of Consciousness
  - Partial Seizures Evolving into Generalized Seizures

- Generalized Seizures
  - Absence (Petit Mal)
    - Staring Spells
  - Myoclonic
    - Single Jerk
  - Atonic
    - Drop Attack
  - Clonic
    - Rhythmic Jerking
  - Tonic
    - Stiffening
  - Tonic-Clonic (Grand Mal)

D. Phases

- Pre-ictal Phase
  - Aura
  - Nausea
  - Confusion
  - Visual or Auditory Changes
  - Precipitating Events

- Ictal Phase
  - Assess
  - Type
  - Sequence of Events
  - Character of Movements

- Autonomic Signs
  - V/S, Respiratory Changes, Incontinence, Salivation, Diaphoresis
- Consciousness

- Post-ictal
  - Level of Consciousness
  - Trauma Survey
  - Muscle Soreness
  - Headache
  - Weakness (Todd's paralysis: post seizure hemiplegia or monoplegia, can last minutes → hours)
  - Aphasia

E. Assessment

- History
- Labs
  - CBC, Chem 20, LFTs, U/A
  - Lactic Acid, ABG
  - Tox screen
- Imaging
  - CT
  - MRI
- EEG

F. Interventions

- ABC's
- Control Seizure
  - Lorazepam (Ativan)
    - Enhances the Inhibitory Neurotransmitter (GABA)
    - Rapidly Crosses the Blood-Brain Barrier
    - Remains in the Brain Longer Than Diazepam (Valium)
    - Cleared by the Liver
    - 2 to 4 mg IV STAT
    - Maximum Dose = 8 mg
  - Anticonvulsants (Antiepileptic Drugs – AED)
    - If Already on an AED, Draw Level
    - Phenytoin (Dilantin), Carbamazepine (Tegretol)
    - Fosphenytoin Sodium (Cerebryx)

- ✔ Remember – Whatever the Patient was on Was **NOT** Enough
- ✔ Consider Adding Additional Agents Immediately
  - Barbiturates
  - Pentobarbital (Nembutal)
  - Short Acting Anesthetic
  - Suppresses Neuronal Activity
  - Significant Respiratory
  - Depressant
  - IV Bolus or Cont. gtt

- Nursing Care
  - ✔ Seizure Precautions
  - ✔ Airway
  - ✔ Safe Environment
  - ✔ Don't Restrain
  - ✔ Don't Leave the Patient
  - ✔ Observe..Observe..Observe
  - ✔ Monitor..Monitor..Monitor
  - ✔ Reassure Patient and Family

VIII. Traumatic Brain Injury

A. Common Causes

- Blunt
  - ◆ MVC
  - ◆ Falls
  - ◆ Sports
- Penetrating
  - ◆ Gun Shot Wounds
  - ◆ Impalements
- Acceleration and Deceleration
- Primary vs Secondary

B. Definitions

- Contusion
  - ◆ Bruising of Brain Tissue
- Concussion
  - ◆ Microscopic, Diffuse Damage of Tissue
- Hemorrhage
  - ◆ Bleeding into or Around Tissue

- Diffuse Axonal Injury
  - Tearing and Stretching of Axons (deep white tracts)
- Skull Fractures

C. Injuries

- Tissue Damage
- Bleeds
  - Epidural - Arterial
  - Subdural – Venous: Acute, Subacute, Chronic
  - Intercranial
  - Subarachnoid – Most Common
  - Hematomas
- Increased ICP
- Skull Fractures
  - Linear, Compound or Depressed
  - Basilar Fx
    - ✔ Five Bones Form Base: Occipital, Ethmoid, Frontal, Sphenoid, Temporal
    - ✔ Anterior Fx: Raccoon's Eyes, Rhinorrhea
    - ✔ Middle Fx: Battle's Sign, Otorrhea

D. Management

- Monitor & Manage ICP
  - Brain, Blood, CSF
- Intubate & Oxygenate
- Treat Problem
- Pharmacology
- Decrease Neuro Demands
- Decrease All Demands
- Seizure Prevention

IX. Space Occupying Lesions

Brain Tumors

- Primary vs. Secondary
- Benign vs. Malignant
- Males > Females (5th -7th decade)
- Location:

- Adult: Supratentorial
- Children: Infratentoral

- Types:
  - Glioma: Higher grade (I-IV) the more malignant
  - Meningioma: arises from meninges and surrounds brain
  - Neuromas: aka schwannomas, noninvasive and slow growing
  - Pituitary Adenomas: secretory or nonsecretory

A. **Clinical Presentation** (space occupying)
- Compression on Brain
- Infiltration of Tissue
- Disruption of Blood-Brain Barrier
- Cerebral Edema
- CSF Obstruction (Hydrocephalus)
- Tumors are Vascular and May Bleed
- Elevated ICP
- Seizures
- Hormonal Abnormalities (DI, SIAHD)
- Focal Deficits

B. Treatment
- Surgery
  - Remove Lesion
  - Decrease Compression
  - Relieve Symptoms
  - Shunt Placement
- Medications
  - Steroids (dexamethasone- decrease vasogenic cerebral edema)
  - Anticonvulsants
  - Chemotherapy
- Radiation
- Symptomalogical tx only
- Nursing Concerns
  - Intracerebral Bleed
  - Stroke
  - Hydrocephalus
  - Cerebral Edema

- Infection
- CSF Leak
- DVT Risk

X. Summary

Nursing Care of ALL Neuro Patients

- Respiratory Support
- Nutrition
- Skin, Mobility
- DVT & Ulcer Prophylaxis
- Bowel and Bladder Support
- Patient & Family Emotional Support